

The Oravital™ System: A Paradigm Shift in the Treatment of Periodontal Disease

Kerry Hyland-Lepicek, RDH

There is substantial evidence indicating that most forms of periodontal disease are specific infections caused by an overgrowth of mainly anaerobic bacteria species. Standard treatment for periodontal disease is mechanical debridement and successful treatment can be associated with the reduction in levels of these anaerobes in the dental plaque, thus improving periodontal health.¹ Patients may experience a temporary reduction of bacteria levels leading to clinical improvement but if oral home care does not adequately disrupt the biofilm, bacteria will quickly return to pre-debridement levels.

The present standard of care recommends that patients return

at 3 to 6 month intervals for life to have the teeth “cleaned”¹ without eliminating the infection. Studies show that dental cleanings are not sufficient to eliminate the source of the infection.² The emerging evidence that periodon-

Biofilm analysis is a major component of diagnosis and identifies the underlying infection

titis contributes to cardiovascular disease, diabetes, osteoporosis and respiratory conditions indicates that patients now rely on the dental team not just for their oral health but for their systemic health as well. This requires a paradigm shift of considerable magnitude, namely, from treating plaque accumulations to treating a chronic infection.

DIAGNOSIS OF PERIODONTAL INFECTION

The clinician who is treating oral infection requires tests that identify the extent of infection as well as the source. Gingival tissue examination, probing for pocket depth and recording bleeding on probing are necessary tests that visually identify existing periodontal disease. What is

lacking is location and composition of biofilm responsible for the infection. The inclusion of a microbiology assessment of oral biofilm from the teeth and tongue tests for presence as well as location of oral pathogens and provides that information. Periodic sampling post treatment provides an avenue to monitor shifts in the biofilm and provide the dental

team with advance warning of potential infection.

TREATMENT OF PERIODONTAL INFECTION

The standard for treatment of most infections, systemic or oral, may require the use of an antibiotic. Bacteriological findings indicate that most forms of periodontal disease are anaerobic infections associated with the overgrowth of *P. gingivalis*, *T. denticola*, *F. nucleatum* and others. This overgrowth of anaerobic flora can be altered by the use of antibiotics followed by a maintenance regimen of selected antimicrobial agents.

FIVE STEP APPROACH TO ORAL HEALTH

The Oravital™ System has been developed and administered over a period of 17 years as a diagnostic and treatment system for oral infections, specifically gingivitis, mild to moderate periodontal disease and breath odour. Biofilm analysis is a major component of diagnosis and identifies the underlying infection. Antibiotic rinses form the treatment component and are used for two weeks, three times a day. These rinses, made up of antibiotic particles suspended in an antifungal solution, travel into the sulcus and are effective in decreasing bleeding and pocket depth (Figure 1).

Once balanced, the biofilm is maintained by an antimicrobial rinse combination designed to balance the Gram-negative and the Gram-positive groups of oral bacteria. The Oravital™ system promotes a Five Step program in attaining oral health (Figure 2).

CASE STUDIES USING THE ORAVITAL™ SYSTEM

Patients were randomly selected from a pool of approximately 150 patients that were treated using the Oravital™ system in our general practitioner's office. Patients

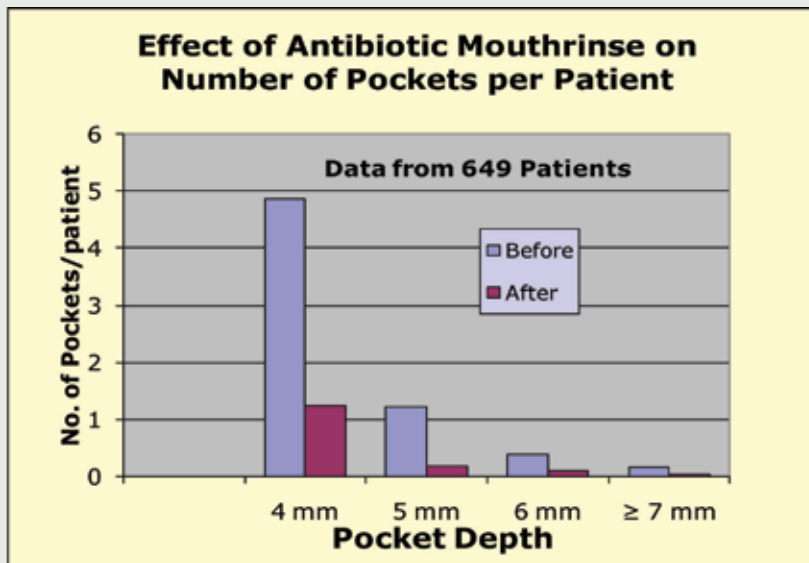


FIGURE 1—Antibiotic Effect after Two Weeks of Rinsing (p-value =.00001).

ORAVITAL™ SYSTEM	PROCEDURE	OUTCOME
STEP 1: DIAGNOSIS Appointment 1	Send biofilm samples of the teeth and tongue to lab for Gram stain analysis. Take periodontal measurements. Take X-rays when required.	Establishes the presence of infection. Provides a baseline to measure improvement.
STEP 2: TREATMENT Appointment 1	Debride as required. Prescribe a topical antibiotic rinse for two weeks. Review disruption of biofilm.	Reduces oral pathogens. Biofilm shifts to healthy. Decreases bleeding points, pocket depth and number.
STEP 3: EVALUATION Appointment 2	Record and evaluate changes. Record localized areas that may require additional treatment. Use an antibiotic cream, laser, etc to treat local infection.	Controls overall infection. Makes localized areas easier to treat. Patient experiences a healthy oral environment.
STEP 4: MAINTENANCE Appointment 2	Select maintenance rinses based on patient needs. Evaluate patient's disruption of biofilm.	Balances the oral biofilm and prevents a shift from health to disease.
STEP 5: MONITOR PATIENT'S BIOFILM	Collect bacterial samples every 6 to 12 months. Identify shifts from health to disease and retreat when necessary.	Allows the clinician to intercept and treat infection at an early stage.

FIGURE 2—The Oravital™ Five Steps in the Treatment of Mild to Moderate Periodontal Disease

* #	MEDICAL HISTORY	PRETREATMENT MICROBIOLOGY	TREATMENT	MAINTENANCE SYSTEM	# YEARS PATIENT
1.	Hypertension	Moderate gram-negative bacteria	Antibiotic rinse	Chlorhexidine and Smartmouth(tm)	2
2.	Healthy	Many gram-negative bacteria & vibrios	Antibiotic rinse	Chlorhexidine	12
3.	Hypertension	Many gram negative bacteria	Antibiotic rinse	Chlorhexidine and Smartmouth(tm)	14
4.	Type II Diabetes	Moderate gram-negative bacteria	Antibiotic rinse	Chlorhexidine and CloSYS	7
5.	Healthy	Many gram-negative bacteria & moderate vibrios	Antibiotic rinse	Chlorhexidine and Smartmouth(tm)	7
6.	Hypertension	Many gram negative bacteria	Antibiotic rinse	Chlorhexidine and Smartmouth(tm)	33
7.	Hiatal hernia	Moderate gram-negative bacteria & vibrios	Antibiotic rinse	Chlorhexidine and CloSYS	3
8.	Recovering drug addict	Many gram-negative bacteria & moderate vibrios	Antibiotic rinse	Chlorhexidine and Smartmouth(tm)	6
9.	Healthy	Very many gram-negative bacteria & moderate vibrios	Antibiotic rinse	Smartmouth(tm)	27
10.	Healthy	Many gram-negative bacteria, vibrios & spirochetes	Antibiotic rinse	Chlorhexidine and Smartmouth(tm)	7

FIGURE 3—Summary of patient history, microbiology and maintenance. (* In all cases the medical condition is controlled)

in this office were given options for treatment including scaling only, referral to a periodontist and/or the Oravital™ system. All these patients were on a 3-4 month hygiene recare system and have continued to come in every 3-4 months. Oral hygiene was moderate to good in all patients. Except for patient # 1, whose clinical information was collected prior to scaling, information for the Oravital™ initial appointment was collected four to six weeks after scaling was completed.

During the Oravital™ first appointment, all patients had a medical history update (Figure 3) and an examination that included bleeding on probing and pocket measurements. (Figure 4).

Despite regular 3 months recare visits, we were not able to reduce the persistent but mild periodontal disease

Oral microbiology samples were taken from the teeth and tongue before treatment and after treatment and were analysed using the Gram-stain technique (Figure: 5). Patients were disclosed and instructed on oral bio-film disruption.

All patients rinsed with an antibiotic rinse three times a day for two weeks. At the second appointment all the measurements were retaken, including bleeding on probing, pocket measurements and microbiology samples. The patients were then placed on a

maintenance program that included a selection of rinses. The most common system of maintenance was the use of chlorhexidine 0.2% for two weeks fol-

lowed by either, zinc ion based rinse (Smartmouth?) or a sodium chlorite based rinse (CloSYS) (Figure: 3).

INDIVIDUAL CASE STUDIES

The following individual case studies compare bleeding on probing and pocket depth as measured at Appointment 1 and again at Appointment 2 after two weeks of treatment with the antibiotic rinse.

CASE STUDY FOR PATIENT #1, A 59-YEAR-OLD FEMALE WITH CONTROLLED HYPERTENSION

As a patient of record for 2 years,

PATIENT INFORMATION			APPOINTMENT 1					APPOINTMENT 2 AFTER TWO WEEKS OF TREATMENT				
NAME	AGE	GENDER	BOP	4MM	5MM	6MM	7MM +	BOP	4MM	5MM	6MM	7MM+
1	59	F	121	33	0	0	0	11	0	0	0	0
2	60	M	70	23	2	0	0	12	8	0	0	0
3	49	F	63	22	1	0	0	15	2	0	0	0
4	56	M	40	6	1	1	0	6	3	0	0	0
5	49	M	81	54	4	1	0	21	27	4	0	0
6	52	M	70	22	4	0	0	9	5	2	0	0
7	63	M	43	16	1	0	0	2	5	0	0	0
8	42	M	80	16	0	0	0	14	6	0	0	0
9	66	M	103	58	21	11	4	35	38	11	8	0
10	66	M	92	27	4	0	0	12	5	0	0	0
TOTAL:			763	277	38	13	4	137	99	17	8	0

FIGURE 4—Summary of Changes in Bleeding Points and Periodontal Pockets between.

ORAL MICROBIOLOGY REPORT			
MICROSCOPY RESULT	TONGUE BASE	TONGUE DORSUM	TEETH
Gram-Positive Bacteria			
Cocci	High	High	High
Bacilli	Moderate	Moderate	Very High
Gram-Negative Bacteria			
Cocci	High	High	Moderate
Bacilli	Moderate	Low	High
Fusiforms			Moderate
Spirochetes			Moderate
Vibrio			Moderate
Yeast			Low
WBC	Low		Low
Notes: Green is healthy: Orange is concern : Red is harmful			

SAMPLE TAKEN FROM THE TEETH

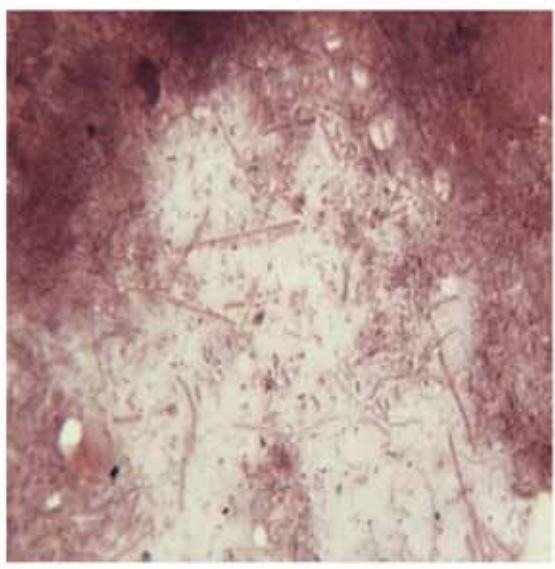


FIGURE 5—Oral Microbiology Report and Sample of Dental Biofilm.

her chief complaint was gingival bleeding and odour between her teeth. After treatment, there is a 91% reduction in BOP and 100% reduction in 4 mm pockets. Two years after the initial treatment, the patient reported localized bleeding on flossing. Measurements and microbiology were retaken and the patient was retreated.

CASE STUDY FOR PATIENT #3, A 49-YEAR-OLD FEMALE WITH CONTROLLED HYPERTENSION

As a patient of record for 14 years, her moderate to severe gingivitis did not improve despite 3-4 month periodontal maintenance,. After treatment, her tissues improved considerably and continue to be minimal two years after treatment. Retreatment has not been needed.

She uses a chlorhexidine rinse twice a week and Smartmouth? rinse on the other 5 days.

CASE STUDY FOR PATIENT #4, A 56-YEAR-OLD MALE WITH CONTROLLED TYPE II DIABETES

Despite regular 3 months recare visits, we were not able to reduce the persistent but mild periodontal disease. He refused a referral

to a periodontist and asked if we had any other treatments that could help him. Following treatment, the patient was very pleased with his results. 5 and 6mm pockets are now 4mm.

CASE STUDY FOR PATIENT #9, A 66-YEAR-OLD HEALTHY MALE

Patient #9, a patient of record for 27 years, has maintained good oral hygiene and regular 3-month hygiene debridement appointments with little periodontal improvement. He has refused to be referred for periodontal surgery. After treatment this patient uses SmartMouth™ daily as his maintenance protocol.

Patients can see a difference in just two weeks and this increases their commitment to regular dental care

CASE STUDY FOR PATIENT #10, A 66-YEAR-OLD HEALTHY MALE

Although he was on a 4 month maintenance schedule, the patient developed severe gingivitis around a recently placed implant in 4.4. The antibiotic treatment was successful and restored the tissue around the implant to a healthy state. He is currently using chlorhexidine and SmartMouth™ as his maintenance routine.

SUMMARY

The Oravital™ approach is a unique system that enhances the existing periodontal program in a dental practice and provides patients another non-surgical option. Oravital™ treatment can be used for all patients who have

	APPOINTMENT 1	APPOINTMENT 2	TWO YEARS LATER
BOP	121	11	41
4mm	33	0	4
5mm	1	0	0

FIGURE 6—Patient #1 results.

	APPOINTMENT 1	APPOINTMENT 2	TWO YEARS LATER
BOP	63	15	11
4mm	22	2	3

FIGURE 7—Patient #3 results.

	APPOINTMENT 1	APPOINTMENT 2
BOP	40	6
4mm	6	3
5mm	1	0
6mm	1	0

FIGURE 8—Patient #4 results.

	APPOINTMENT 1	APPOINTMENT 2	TWO YEARS LATER
BOP	103	35	66
4mm	58	38	35
5mm	21	11	12
6mm	11	8	5
7mm+	4	0	0

FIGURE 9—Patient #9 results.

	APPOINTMENT 1	APPOINTMENT 2
BOP	92	12
4mm	27	4
5mm	4	0

FIGURE 10—Patient #10 results.

gingivitis, early to moderate periodontitis, breath odour and for those patients who refuse periodontal surgery. Patients can see a difference in just two weeks and this increases their commitment to regular dental care. The Oravital™ system provides patients with an easy option to obtain periodontal health. **OH**

REFERENCES

1. Loesche, WJ. and Grossman, N.S.: Periodontal disease as a specific, albeit chronic, infection: diagnosis and treatment. *Clinical Microbiology Reviews*. 14(4):727-752;2001.
2. Loesche, WJ.: Anaerobic Periodontal Infections as Risk Factors for Medical Diseases. *Current Infectious Disease Reports*. 1:33-38, 1999.

Brief bio will go here

Oral Health welcomes this original article.